

Idiopathic Non-Specific Interstitial Pneumonia

What is Idiopathic Non-Specific Interstitial Pneumonia?

Idiopathic Non-Specific Interstitial Pneumonia, or “idiopathic NSIP”, is a chronic lung disease in which inflammation and/or scar tissue (“fibrosis”) builds up in the walls of the air sacs of the lungs.

What are the symptoms of idiopathic NSIP?

Early in the disease, most people with idiopathic NSIP will have no symptoms or might have a bothersome cough. In more severe disease, breathlessness during exercise and daily activities becomes common. Fatigue, depression, and anxiety are also commonly experienced by people living with idiopathic NSIP.

What causes idiopathic NSIP?

Although the word “idiopathic” means “of unknown cause,” there is evidence that abnormalities in the immune system may be a cause of idiopathic NSIP. Your body’s immune system helps fight off infection by attacking bacteria and viruses. Many people with idiopathic NSIP have abnormal blood tests that suggest autoimmunity may be present. Some of these blood tests include an anti-nuclear antibody (ANA) test, rheumatoid factor (RF) test, and others. Sometimes – for reasons we don’t really understand – your body’s immune system can begin attacking your own tissues and organs, causing inflammation and scarring. This is known as “autoimmunity.” “Auto” means “self,” so “autoimmunity” means that the immune system is attacking your own body.

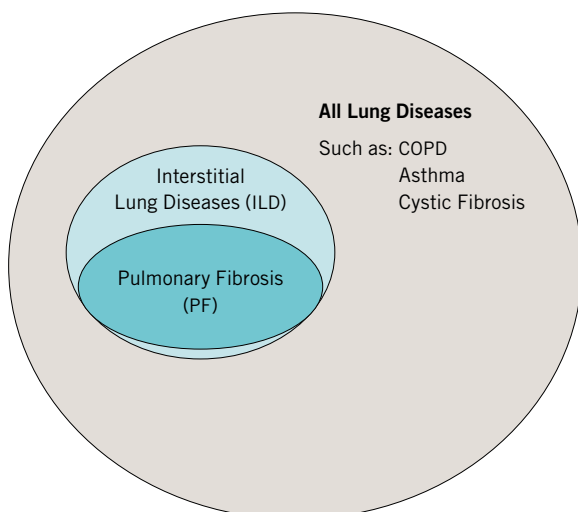
What makes it different from other forms of PF?

It is important first to understand that idiopathic NSIP falls into a large category of diseases called “interstitial lung diseases” or “ILD.” There are over 200 types of ILD. Most ILDs have either fibrosis or inflammation (or both) in the walls of the air sacs. “Pulmonary fibrosis” (PF) is used to refer to any type of ILD in which fibrosis (also known as scarring) is present, and since most forms of ILD include fibrosis, most forms of ILD are also forms of PF.

Idiopathic NSIP is one type of ILD. Most people with idiopathic NSIP have scarring. Many have both inflammation and scarring. Only a few have inflammation without scarring.

Since idiopathic NSIP is often caused by “autoimmunity,” it is closely related to a different family of ILDs called “connective tissue disease-related interstitial lung diseases.”

Because it is often caused by “autoimmunity”, many people with idiopathic NSIP may also carry a diagnosis of “idiopathic pneumonia with autoimmune features” or “IPAF.” A diagnosis of IPAF means that both autoimmunity and ILD are present. Many people with IPAF have idiopathic NSIP, but some will have other forms of ILD.



TYPE OF PF	CLUES THAT DOCTORS USE
Drug-Induced	Prior or current use of amiodarone, nitrofurantoin, chemotherapy, methotrexate, or other drugs known to affect the lungs
Radiation-induced	Prior or current radiation treatment to the chest
Environmental (called hypersensitivity pneumonitis)	Exposure to mold, animals, or other triggers
Autoimmune (called connective tissue disease-related)	Joint inflammation, skin changes (particularly on the fingers and face), dry eyes or mouth, abnormal blood tests
Occupational (called pneumoconiosis)	Prior or current exposure to dusts, fibers, (called pneumoconiosis) fumes, or vapors that can cause PF (such as asbestos, coal, silica, and others)

I was told I have “NSIP” but no one told me it was “idiopathic.” Are there other forms of NSIP?

Yes. NSIP refers to the visual pattern of inflammation and/or scarring on a CT scan (image) or in lung tissue obtained from a lung biopsy. There are many causes of NSIP, including connective-tissue disease (CTD-ILD) and certain medications. When no cause can be identified, a diagnosis of idiopathic NSIP is often made.

How is idiopathic NSIP diagnosed?

When a doctor or other healthcare provider suspects that a patient has ILD, they will perform tests that might include pulmonary function tests, a chest x-ray, blood work, and a high-resolution CT scan. Pulmonary function tests measure how much air the lungs can hold. The more scar tissue the lungs have, the less air they will hold. A doctor will also use a special kind of X-ray of the chest, called a high-resolution computed tomography (HRCT) scan, which gives detailed images of the lung. Healthy lung tissue looks nearly black on a CT scan (also known as CAT scan). Scar tissue and inflammation both appear grey or white. In some cases, a diagnosis of idiopathic NSIP can be made from these tests. In many cases, a lung biopsy may need to be performed.

How is idiopathic NSIP treated?

There are no guidelines or clinical trials available to help clinicians make treatment decisions. When inflammation is present in the lung (which can be seen on a CT scan or lung biopsy), medications that weaken the immune system (“immunosuppressants”) are often used. There is no “right” medication for everyone, and sometimes monitoring your disease without medication is appropriate.

Some medications that doctors might use to treat idiopathic NSIP include “steroids” (such as prednisone), mycophenolate mofetil, azathioprine, and others. Pirfenidone and Nintedanib have not been studied in idiopathic NSIP. We do not know if these medications are effective to treat idiopathic NSIP.

Lung transplantation is an appropriate treatment for some people living with idiopathic NSIP. Early evaluation for lung transplant is important because the process involves a series of appointments to provide the patient with information about transplantation and to determine if they are an appropriate candidate.

Pulmonary rehabilitation, supplemental oxygen, smoking cessation, routine vaccinations (such as influenza and pneumonia vaccination) are important parts of living with idiopathic NSIP. You can learn more about supplemental oxygen at: <https://www.pulmonaryfibrosis.org/life-with-pf/oxygen-therapy>. You can learn more about pulmonary rehabilitation at: <https://www.pulmonaryfibrosis.org/life-with-pf/pulmonary-fibrosis-treatment-options>

What is my prognosis?

In many cases, idiopathic NSIP is a progressive disease, which means that inflammation and/or fibrosis builds up over time, gradually causing worsening breathlessness and the need for increasing amounts of oxygen. Eventually, lung failure (medically called “respiratory failure”) can develop, which is a life-threatening condition.

In some cases – particularly when no fibrosis is present – idiopathic NSIP may be only slowly progressive or may remain stable for many years. It is important for you to know that there is no way to predict how long someone with idiopathic NSIP will live. Some people live for many years. Others – even despite taking medications – will develop respiratory failure even within just months or years after their diagnosis. No one can predict exactly how long you will live with idiopathic NSIP. Everyone is different. Your doctor can give you more detailed information about your prognosis.

Are there experimental therapies available?

You can search for research studies closest to you on our PFF Clinical Trial Finder: trials.pulmonaryfibrosis.org.

Acknowledgements

The Pulmonary Fibrosis Foundation is thankful to the following for their assistance in writing and reviewing this fact sheet:

David J. Lederer, MD, MS
New York Presbyterian/Columbia University Medical Center
New York, NY
PFF Senior Medical Advisor, Education and Awareness