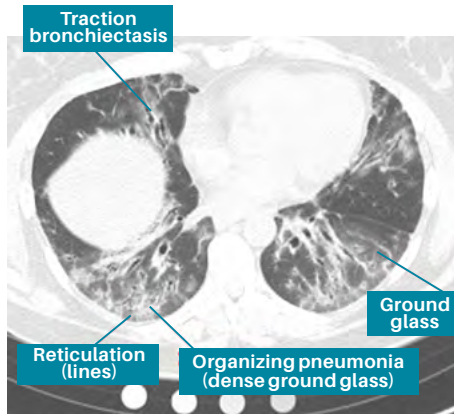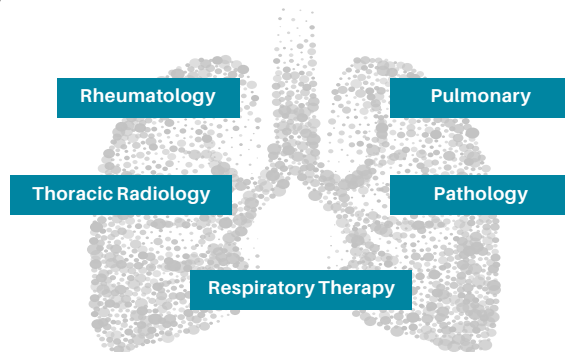


*HRCT images courtesy of Gregory P. Cosgrove, MD

A multidisciplinary discussion (MDD) for patients suspected to have CTD-ILD has many benefits and is crucial to the diagnostic process. MDD can increase diagnostic confidence by refining a provisional diagnosis, enhance interobserver agreement on the diagnosis, and increase diagnostic precision. It is important that CTD patients with evidence of respiratory disease are referred to a pulmonologist. In addition to rheumatology and pulmonary, other areas of specialty that are often involved in MDD for CTD-ILD include thoracic radiology, and pathology. Patients benefit from improved care coordination when MDD is utilized.



Mitto S, Fell CD. Semin Respir Crit Care Med 2014;35:249.

SUPPORT FOR YOU FROM THE PULMONARY FIBROSIS FOUNDATION

The mission of the Pulmonary Fibrosis Foundation is to accelerate the development of new treatments and ultimately a cure for pulmonary fibrosis. Until this goal is achieved, the PFF is committed to advancing improved care of patients with PF and providing unequalled support and education resources for patients, caregivers, family members, and health care providers.

To learn more about how the PFF can help support you, contact the PFF Help Center at **844.TalkPFF** (844.825.5733) or **help@pulmonaryfibrosis.org**, or visit the PFF online at **pulmonaryfibrosis.org**.

Acknowledgements

Elizabeth Volkman, MD, MS
University of California, Los Angeles Medical Center
Los Angeles, CA



SPONSORED BY:



Understanding
Connective Tissue
Disease-Related
Interstitial Lung Disease

RHEUMATOLOGY POCKET GUIDE

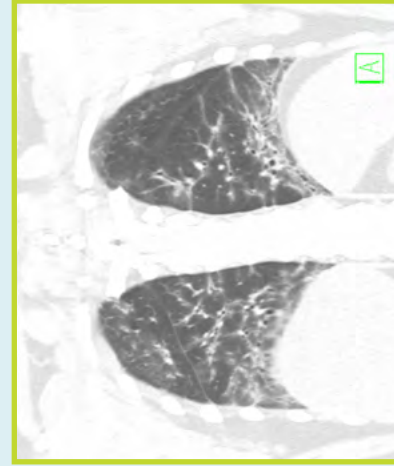
**TABLE 1:
DIAGNOSTIC CLUES THAT SUGGEST IILD IN THE SETTING OF A PREVIOUSLY DIAGNOSED CTD**

Clues	Symptoms	Signs	Physiologic	Radiographic
Early- Fatigue/Dyspnea on exertion	Crackles on auscultation	Restrictive pattern on PFTs - Low FVC - Low TLC	High-resolution chest CT findings consistent with IILD Reticulation (peripheral “lines” in the subpleural space)	
Late- Dyspnea at rest	Crackles on auscultation Digital clubbing Oxygen desaturation with exercise or at rest	Diffusion Impairment - Low DLCO	Ground glass (hazy) opacities and/or Traction bronchiectasis (dilation of the airways larger than the adjacent blood vessel) Honeycomb change (peripheral, subpleural “cysts” in rows)	

Tips
Many patients are asymptomatic in early IILD Symptoms may be nonspecific
Certain CTDs have specific risk factors for IILD as described in Table 2.
Early in course of IILD, PFTs may be normal, or there may be an isolated decrease in the DLCO
NSIP is the most common radiographic pattern of IILD in CTD

TABLE 2: PREVALENCE AND RISK FACTORS FOR IILD BASED ON THE UNDERLYING CTD

	Prevalence of IILD	Risk factors on history and physical	Risk factors based on laboratory studies
Systemic sclerosis	>65%	Male sex African American race Diffuse cutaneous sclerosis	Scl-70 antibody PM/Scl antibody
Rheumatoid arthritis	30-76%	Male sex Older age Cigarette smoking	RF antibody CCP antibody
Sjogren’s syndrome	25%	Male sex Older age Cigarette smoking	ANA antibody RF antibody
Myositis	23-65%	Amyopathic dermatomyositis Older age Arthritis	Jo-1 (PL-1) antibody PL7 antibody PL12 antibody MDA5 antibody
Systemic lupus erythematosus	3-13%	Not well defined	dsDNA antibody
Mixed connective tissue disease	18-66%	Older age Raynaud phenomenon Dysphagia	Anti-Smith antibody



*

Non-specific interstitial pneumonia (NSIP) is the most common HRCT pattern seen in lung disease associated with CTD, although other interstitial patterns, such as usual interstitial pneumonia, are possible. The NSIP pattern is more commonly related to CTD than idiopathic NSIP. Distinctive characteristics seen in NSIP are symmetric, bibasilar, ground glass, reticulation, traction bronchiectasis (dilation and distortion of the bronchi or bronchioles in areas of fibrosis), and subpleural sparing.¹

¹References:

Capobianco J, et al. Radiographics 2012; 32: 33-50.
 Ahuja J, et al. Radiol Clin N Am 2016; 54: 1015-1031.
 Mueller-Mang et al. Radiographics 2007; 27: 595-615.
 Hansell et al. Radiology 2008; 246:697.